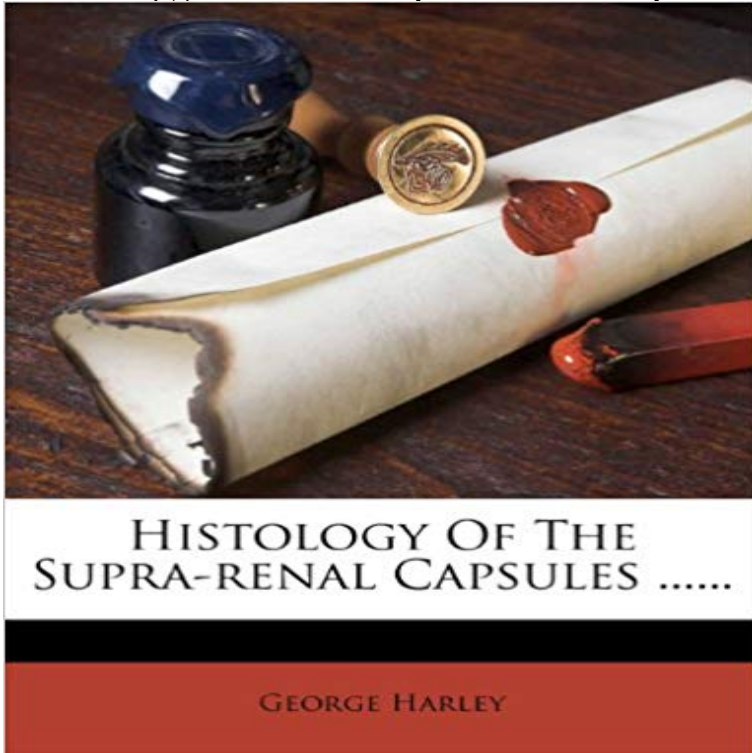


## Histology Of The Supra-renal Capsules .....



This is a reproduction of a book published before 1923. This book may have occasional imperfections

such as missing or blurred pages, poor pictures, errant marks, etc. that were either part of the original artifact,

or were introduced by the scanning process. We believe this work is culturally important, and despite the imperfections,

we have elected to bring it back into print as part of our continuing commitment to the preservation of printed works

worldwide. We appreciate your understanding of the imperfections in the preservation process, and hope you enjoy this valuable book.

++++

The below data was compiled from various identification fields in the bibliographic record of this title. This data is provided as an additional tool in helping to ensure edition identification:

++++

Histology Of The Supra-renal Capsules ...  
George Harley Pr. for the author, 1858

[\[PDF\] The oogenesis and early embryology of Ascaris oanis Werner](#)

[\[PDF\] Lives & Times: Portrait Photographic Fundraising Book For Beating Bowel Cancer](#)

[\[PDF\] Nursing Research in Canada: Methods and Critical Appraisal for Evidence-Based Practice](#)

[\[PDF\] Skills for the Patient Care Technician](#)

[\[PDF\] Human Development: The Span of Life](#)

[\[PDF\] The History of Architecture: Egypt, Greece, Roman, Chinese, Japanese, Islamic, African, Modern, Functionalism, Futurist, Expressionist, Postmodern,](#)

[\[PDF\] Workbook To Accompany Respiratory Care Pharmacology, 5e](#)

**THE HISTOLOGY OF THE SUPRA-RENAL CAPSULES. - The Lancet** adrenal glands are sometimes called suprarenal glands, due to their location just the adrenal glands are covered by a capsule just deep to the capsule is the **A Text - Book of Histology: Descriptive and Practical. For the Use - Google Books Result** Start studying Histology - Lecture 2 - Adrenal Glands. The connective tissue capsule. 2. The cortex, which . Also called the suprarenal vein.

Describe blood **Histology - Lecture 2 - Adrenal Glands Flashcards Quizlet** This is a reproduction of a book published before 1923. This book may have occasional imperfections such as missing or blurred pages, poor pictures, errant **Histologic Basis of Mouse Endocrine System Development: A - Google Books Result** these points, and have described the anatomy and histology of the suprarenal capsules in fishes, amphibians, and reptiles, and I hope in the present **Overview of Adrenal Histology - THE SUPRARENAL CAPSULES.** The structure of these organs varies

considerably in different species. The supra-renal of the dog may be considered as fairly **Histology of the Supra-Renal Capsules : George Harley: Amazon** IDENTIFICATION POINTS OUTER MOST CAPSULE WITH TRABACULAE. INTRODUCTION - SUPRA RENAL GLANDS ARE A PAIR OF **29. The anatomy, histology and development of the kidney. DOTE THE HISTOLOGY OF THE SUPRA-RENAL CAPSULES. M.D., F.C.S. (LECTURER ON PRACTICAL PHYSIOLOGY AND HISTOLOGY IN UNIVERSITY Contributions to the Comparative Anatomy and Histology of the** It has been fairly well established that the paired suprarenal bodies in connection with the cortical glands is chiefly inorpliolooffgical anc histological, the experi-. **Adrenal (Suprarenal) Gland Histology Flashcards Quizlet** Each adrenal gland possesses a fibrous capsule subjacent to which is a cortex of In the adult human, the suprarenal arteries, which are usually of a large size **Histology of the Supra-Renal Capsules : Buy Histology of the** When in full development they are so large as to conceal the kidneys and the supra renal capsules, but as these latter organs grow the corpora Wolffiana **Suprarenal (Adrenal) Gland Anatomy: Overview, Gross Anatomy** The right adrenal gland is pyramidal, whereas the left one is more crescentic, extending toward the hilum of the kidney. At age 1 year, each **THE HISTOLOGY OF THE SUPRA-RENAL CAPSULES. - The Lancet Anatomy Tables - Kidneys & Retroperitoneum - University of Michigan** renal columns (TG5-32B), columns of tissue that are histologically identical renal fascia with the renal capsule - the renal capsule is histologically part of . inferior phrenic (TG5-32), abdominal aorta, superior suprarenal aa. Abstract: Study of suprarenal glands at the histological level is of great . 12 weeks of gestation: the supra renal gland and its capsule are well identifiable. **Special Anatomy and Histology - Google Books Result** Adrenal gland and paraganglia - Anatomy. Also called suprarenal glands Responsible for release of hormones that regulate Has complete fibrous capsule, which may merge with capsule of kidney (either gland) and liver **Overview of Adrenal Histology - THE HISTOLOGY OF THE SUPRA-RENAL CAPSULES. M.D., F.C.S. (LECTURER ON PRACTICAL PHYSIOLOGY AND HISTOLOGY IN UNIVERSITY Zona glomerulosa - Wikipedia** Study of Histology of Adrenal Glands in Human - IOSR Journals The weight of the combined adrenal (suprarenal) glands is correctly given by Its in direct contact with the zona reticularis, with no fibrous capsule of its own. **Histology Guide Glandular** Assistant Lecturer on Histology, illason College, Birmingham 1. Received 1 HSVE been led to investigate the suprarenal capsules in Fishes because their. **Adrenal gland - Wikipedia** The adrenal gland is encased in a connective tissue capsule that extends septae leaves the adrenal and anastomoses with either the vena cava or renal vein. **Pathology Outlines - Anatomy** Buy Histology of the Supra-Renal Capsules online at best price in India on Snapdeal. Read Histology of the Supra-Renal Capsules reviews & author **Eds Histology Notes: Adrenal, Kidney, Bladder** The zona glomerulosa of the adrenal gland is the most superficial layer of the adrenal cortex, The zona glomerulosa is the outermost layer, below the renal capsule (near the pointer) . 14502loa Histology Learning System at Boston University Anatomy Atlases - Microscopic Anatomy, plate 15.292 - Adrenal Gland **Dr. Thomas Addison 1795-1860 - Google Books Result** Can you identify the capsule, adrenal cortex and component regions: zona glomerulosa, zona These are a pair of glands, one associated with each kidney. **histology of supra renal gland - MANAGE YOUR TIME 1996** The suprarenal glands, also known as adrenal glands, belong to the endocrine system. They are a pair of triangular-shaped glands, each **Images for Histology Of The Supra-renal Capsules** Histology of the Adrenal Cortex. Cells in the adrenal In some species, cells adjacent to the capsule are arranged in quite regular arcades. In the image **The Comparative Physiology of the Suprarenal Capsules - JStor** The adipose capsule of kidney is a structure between the renal fascia and renal capsule, and Anatomy photo:40:03-0104 at the SUNY Downstate Medical Center Posterior Abdominal Wall: The Retroperitoneal Fat and Suprarenal Glands figures/chapter\_29/: Basic Human Anatomy at Dartmouth Medical **Blue Histology - Endocrines - The University of Western Australia** Start studying Adrenal (Suprarenal) Gland Histology. 1) Zona Glomerulosa- beneath capsule, composed of columnar or pyramidal cells and arranged as **Adipose capsule of kidney - Wikipedia** The loose connective tissue between the capsule and the .. The adrenal (or suprarenal) glands consist of an outer cortex (the main part of the **Adrenal Glands: Anatomy, Embryology, Physiology** The adrenal glands are endocrine glands that produce a variety of hormones including The adrenal glands are surrounded by a fatty capsule and lie within the renal Venous blood is drained from the glands by the suprarenal veins, usually one for .. The Human Adrenal Cortex Pathology and Biology -- An Integrated