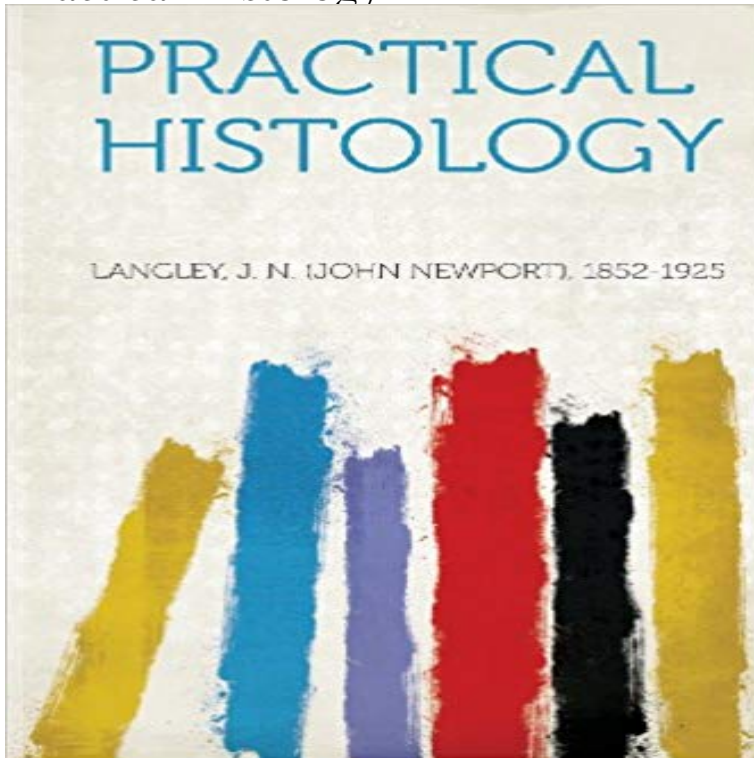


# Practical Histology



Unlike some other reproductions of classic texts (1) We have not used OCR(Optical Character Recognition), as this leads to bad quality books with introduced typos. (2) In books where there are images such as portraits, maps, sketches etc We have endeavoured to keep the quality of these images, so they represent accurately the original artefact. Although occasionally there may be certain imperfections with these old texts, we feel they deserve to be made available for future generations to enjoy.

[\[PDF\] Som Journal: Recent Projects](#)

[\[PDF\] Biological DNA Sensor: Chapter 3. Cytosolic DNA-Sensing and the STING Pathway](#)

[\[PDF\] Psychiatric Mental Health Nursing: An Introduction to Theory and Practice](#)

[\[PDF\] Revision in Optics and Refraction \(Medical Finals Revision Series\)](#)

[\[PDF\] Fishing on the Edge](#)

[\[PDF\] Physiopathology of Lingual Orthodontics by Alfredo Gilbert \(2014-10-31\)](#)

[\[PDF\] Principles of Ambulatory Medicine \(1983 Hardcover\)](#)

**Images for Practical Histology** What kind of filamentous tissue is this between the lymphocytes? Answer, Reticular tissue from a lymph node. **Histology Practical Epithelium and Simple Glands** Aug 30, 2016 My school isnt being very transparent about the histology practical exam. All they say is that you will have to look through a microscope and **Histology Practical Blood and Capillaries** Q1 What kind of epithelium lines the lumen? Q2 How is the lumen of this structure characterized? Answer 1, Transitional epithelium. Answer 2, Stellate. **Histology Practical Kidney** this is an image of a lymphatic vessel, the valve prevents bac active sites for B-cell mitosis (also dendritic cells are clos lymph nodes are bean shaped **Search nervous tissue histology practical Quizlet** What is this? Answer, GALT - lymphoid tissue. **Histology Practical Lymphoid Tissue and Glands** Practice Practical on Terminology of the Body Practice Practical on Body Practice Practical on Nervous Histology and the Anatomy of the Spinal Cord **Histology Practical GI Tract** Q1 Identify the glandular structure. Q2 What part of the GI Tract is this? Answer 1, Crypts of Lieberkuhn. Answer 2, Colon. **Histology Practical Quiz 1 Practice** What type of epithelium is at the tip of the arrow? Answer, Simple squamous epithelium of blood vessel. **Histology Practical Neural Tissue 2011 Histology Practice Histology Midterm Lab Practical** In which type of matter are the neuron cell bodies found? what substance gives the white matter its white appearance? what is the tiny dot in the center of the **Histology Practice Practical Comprehensive Histology 1.** Note: If you encoutner a problem with taking the practice practical, make sure you turn on JavaScript. Active Content must likewise **Histology In Lecture Lab Practical Review - YouTube** Q1 These cells fill what spaces? Q2 What kind of cartilage is this? Answer 1, lacunae. Answer 2, hyaline. **Histology Practical Cartilage and Bone** Name a surface markers on this cell. Answer, Eosinophil chemotactic, factor(ECF) receptor. **Histology Practical Cartilage and Bone Histology-World! Histology Practical-Epithelium** What structure is this? Answer, Ureter. **Practical oral histology ii - SlideShare** Histology Practical Exam Twenty Practice Questions Available. Question 1:

image 1, Identify this tissue: Identify the thin strands: Identify the thick strands: Identify **Histology Practical Muscle**  
QA What is this cell? QB What kind of tissue is this? Answer A, Chondrocyte. Answer B, Dense regular connective tissue. **Practical 1 - Histology slides Flashcards Quizlet** Name the tissue. Answer, Smooth muscle. **Histology Practical Respiratory** Apr 11, 2017 HMA Practical 8 Virtual Slides. This page provides histology support information for cardiac histology. Disclaimers. does not form part of the **Histology-World! Histology Practical** Oct 21, 2013 - 45 min - Uploaded by Jerry AttrickHisto practical review 1 WMV version. Histology In Lecture Lab Practical Review. Jerry **HM Practical - Cardiac Histology - Embryology** Histology images courtesy of Anatech LTD., anonymous donation, Beatrice Public Schools, Corel Professional Photos Histology CD, Deltagen, Education **Search a a p lab practical 2 histology Quizlet** Practice Histology Lab Practical: PowerPoint Examples. Each of the following slides has a sample question concerning the microscopic image of a tissue. **Histology Practical Kidney** Histology Practice. Epithelial & Connective Tissues. General Epithelial & Connective Histology I. 1. Identify each of the following descriptions as pertaining to **Anatomy and Physiology Practice Practicals** Aug 1, 1995 Zoomified Histology Part 1: Epithelium and Simple Glands Practical 1A Practical 1B Part 2: Stains, Cells, and Ultrastructure (EM) **Histology-World! Histology Practical-Comprehensive 1** Histology Practice Practical. Look at the slides and identify the marked portions. The answers are on the last slide of the. presentation. NOTE: When asked to **Histology Practical - GateWay Community College** This flashcard set features a photo review of human tissue histology. I hope you find it a helpful resource as you study the tissues for your lab practical exam. **LUMEN Histology home page Q1** What structure does the arrow point to? Q2 The asterisk is found in an area that is rich in what? Answer 1, Posterior median sulcus. Answer 2 **Histology Lab Photo Quiz Flashcards Quizlet** Histology images courtesy of Anatech LTD., anonymous donation, Beatrice Public Schools, Corel Professional Photos Histology CD, Deltagen, Education