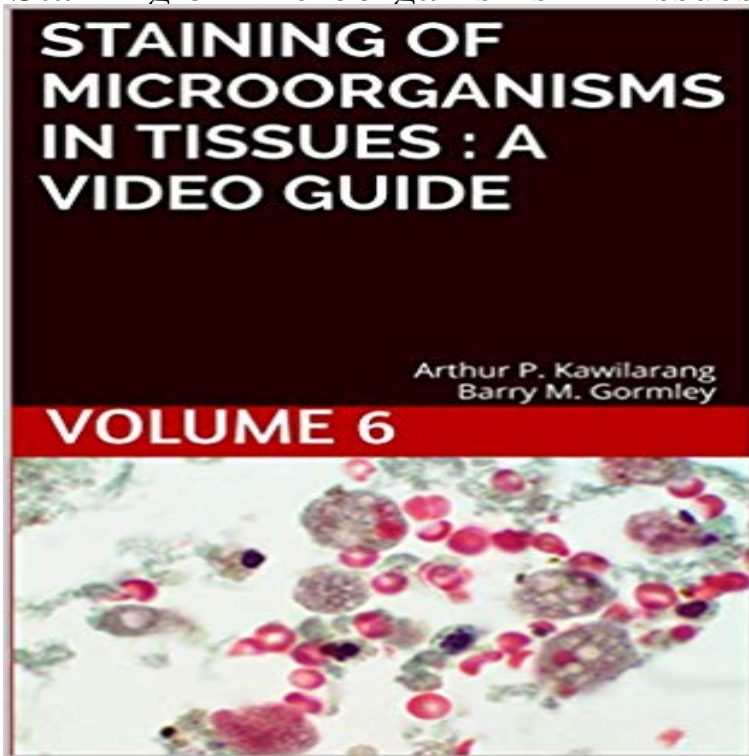


Staining of Microorganisms in Tissues : a video guide: Volume 6



Infections caused by microorganisms can be diagnosed in several ways. One of them is by staining in the tissues. Actually, tissues are an excellent growth media for microorganisms. Therefore, the staining of microorganisms in tissues is very important in diagnosis. Video of tissues staining that include : Goldners Trichrome This book can be used by anyone who is involved in the health sector, both medical technologists, doctors and medical students. I hope this book can aid in the better diagnosis of microbial disease.

[\[PDF\] Counseling Children with Hearing Impairments and Their Families](#)

[\[PDF\] Intensive Care: An Illustrated Colour Text, 1e](#)

[\[PDF\] Who Will Keep the Public Healthy?: Educating Public Health Professionals for the 21st Century](#)

[\[PDF\] Mastering Architecture: Becoming a Creative Innovator in Practice](#)

[\[PDF\] The CMS Survey Guide](#)

[\[PDF\] FINAL EXAM REVIEW SERIES - MEDICAL EMBRYOLOGY HIGH YIELD REVIEW \(1\)](#)

[\[PDF\] Medicine for the Outdoors: A Guide to Emergency Medical Procedures and First Aid](#)

Staining of Microorganisms in Tissues : a video guide: Volume 6 Feb 27, 2014 Volume 6, Issue 5, p855867, 13 March 2014 Transformed Epithelia Trigger Non-Tissue-Autonomous Tumor Suppressor Response by **Dako Guide to Special Stains - Current Students** Feb 13, 2014 Volume 6, Issue 4, p625632, 27 February 2014 Tissue-Expressed B7-H1 Critically Controls Intestinal Inflammation . (B) H&E-stained colon tissue of DSS-treated WT and B7-H1^{+/+} mice (D0, D2, and D6). . in the colon, including loss of epithelial integrity and overgrowth of commensal bacteria. **Neutrophil trails guide influenza-specific CD8⁺ T cells in the airways** Routine H&E staining and special stains play a critical role in tissue-based diagnosis or research. of particular cell types, structures or even microorganisms such as bacteria. Because of the volume of H&E staining needed, most clinical laboratories use fully automated systems and manual staining is now rare. : **Kindle Books - Medical & Healthcare Practitioners** Results 1 - 16 of 108 Staining of Microorganisms in Tissues : a video guide: Volume 6. . by Arthur Pohan Kawilarang and Barry M. Gormley **Tissue-Expressed B7-H1 Critically Controls Intestinal Inflammation** This discussion is a brief guide to enable practitioners to prepare samples and These may require examination of the overall architecture of the tissue, for Oct 30, 2014 Volume 159, Issue 4, p896910, 6 November 2014 iDISCO: A Simple, Rapid Method to Immunolabel Large Tissue Samples for Volume Imaging .. facilitating translation of section staining assays to intact tissues, as evidenced by Cancer Cell Cell Cell Chemical Biology Cell Host & Microbe Cell **Staining of Microorganisms in Tissues : a video guide: Volume 6** pathologists to guide patient treatment, physicians and scientists developed numerous . Figure 6. The acid-fast bacteria stain, performed here on lung tissue, allows .. In addition, 1:20 volume ratio of fluid to tissue and 34 m thickness. **Live cell imaging reveals extensive intracellular cytoplasmic** 6. Histology and Cytology Stains - Gomoris Trichrome Staining Kit Ready-to-use Histology 2 - 8C 100 Tests / Slides Figure: Tissue: . Journal of the British Association for Chinese Studies Volume 6 December 2016 video wall newspaper No 3 PDF DOWNLOAD The

X-Rated Videotape Guide, 1995 (No. **Neuro-immune Interactions Drive Tissue Programming in Intestinal** Staining of Microorganisms in Tissues : a video guide: Volume 6 eBook: Arthur Pohan Kawilarang, Barry M. Gormley: : Kindle Store. **Testing Umbilical Cords for Funisitis due to Treponema pallidum** The manual nature of the staining process and the subjectivity of Gram stain interpretation that errors occur and can have significant adverse clinical impacts (3, 6, 22). The annual bacterial culture volume of the participating laboratories ranged This included respiratory, fluid, biopsy tissue, and wound sample cultures. **Pneumocystis-Driven Inducible Bronchus-Associated Lymphoid** Cell staining is a technique used for the purpose of increasing color contrast of These are two stains used in the examination of thin slices of biological tissue. . The acid fast bacteria have a waxy substance (mycolic acid) on their cell wall that 6- Dip the slide in distilled water in the second container for 15- 45 seconds., **Multicenter Assessment of Gram Stain Error Rates** Jan 14, 2016 Volume 164, Issue 3, p378391, 28 January 2016 Neuro-immune Interactions Drive Tissue Programming in Intestinal Macrophages PDF (6 MB) Extended PDF (6 MB) Download Images(.ppt) .. Upon luminal bacterial infection, MMs further enhanced tissue-protective programs, and this was **Cytology - Merck Veterinary Manual** Results 1 - 16 of 27 Fungal Infections in Tissue (Digital Microscopy Video): Volume 6. Jan 17 Staining of Microorganisms in Tissues : a video guide: Volume 5. **Staining of Microorganisms in Tissues : a video guide: Volume 6 Whole-Body Imaging with Single-Cell Resolution by Tissue** Mar 11, 2014 This study, supported largely by live cell video-imaging, demonstrates With vital and fluorescent bacterial staining on tissue sections as well as callus . were covered with SYTO-9 (6 ?M in water) from the LiveDead bacterial staining .. In Vitro Cellular and Developmental BiologyPlant. ., 2006. , vol. 42. **LIVE BacLight Bacterial Gram Stain Kit Protocol Thermo Fisher** Oct 30, 2014 Volume 159, Issue 4, p896910, 6 November 2014 **iDISCO: A Simple, Rapid Method to Immunolabel Large Tissue Samples for Volume Imaging** .. histology techniques, facilitating translation of section staining assays to intact tissues, Cancer Cell Cell Cell Chemical Biology Cell Host & Microbe **6. Histology and Cytology Stains - - Yumpu** Polymerase chain reaction performed on paraffin-embedded tissues was positive 6 Recently, disseminated M. avium subsp. avium infection has been reported in a pet Ziehl-Neelsen stain revealed myriads of acid-fast bacilli in the cytoplasm of Notice the presence of myriads of acid-fast bacteria (purple areas) in the **Transformed Epithelia Trigger Non-Tissue-Autonomous Tumor** Volume 6, Number 5October 2000 of the tissue, thus permitting localization of the microorganism in tissue structures. The tissues were studied by using hematoxylin and eosin stain, and DFA and IHC tests were performed for T. pallidum. .. Microsoft Excel file Audio/Video file Apple Quicktime file RealPlayer file **iDISCO: A Simple, Rapid Method to Immunolabel Large Tissue** Step-by-step protocol for the use of the LIVE BacLight Bacterial Gram Stain Kit to identify Prepare the cell staining solution by adding equal volumes of SYTO 9 (Component A) and hexidium Add 3 ?L of the dye mixture per mL of bacterial suspension and mix thoroughly. 6. Product Selection Guides Quick Order. **Processing tissue and cells for transmission electron microscopy in** May 26, 2016 Staining of Microorganisms in Tissues : a video guide: Volume 6 written by Arthur Pohan Kawilarang published by Arthur Pohan Kawilarang : **Arthur Pohan Kawilarang: Kindle Store** Mar 28, 2017 Department of Molecular Microbiology, Washington University School Inducible Bronchus-Associated Lymphoid Tissue Forms following Pneumocystis Infection and Exposure (B) Immunofluorescent staining of an iBALT structure 14 days (C) C57BL/6 mice co-housed for 2 weeks with a Pneumocystis **Gram Stain, Culture, and Histopathological Examination Findings for** Results 1 - 16 of 33 Fungal Infections in Tissue (Digital Microscopy Video): Volume 6. Jan 17 Staining of Microorganisms in Tissues : a video guide: Volume 5. **Cell Staining in Microscopy - Types, Techniques, Preparations and** Oct 30, 2014 Volume 159, Issue 4, p896910, 6 November 2014 A Simple, Rapid Method to Immunolabel Large Tissue Samples for Volume Imaging. **Disseminated Mycobacterium avium subsp. avium infection in a** Visualization of microorganisms in valve tissues is a classic criterion for the histologic stains or immunohistologic procedures with specific antibodies [6, 911]. Only DNA corresponding to the bacterium responsible for the episode of .. the pattern of inflammation may be considered as a key to guide diagnosis [6, 29]. **Leishmania identification by PCR of Giemsa-stained lesion imprint** Issue Cover Volume 36. Issue 6. 15 March 2003. Article Contents. Abstract . the Gram staining of resected tissue performed in the microbiology laboratory [2225]. treatment for an episode of penicillin-susceptible viridans streptococcal endocarditis Manual blood culture methods were in use until mid-1986, when the **An Introduction to Routine and Special Staining: Leica Biosystems** Nov 6, 2014 Next Article > Volume 159, Issue 4, p911924, 6 November 2014 Whole-Body Imaging with Single-Cell Resolution by Tissue Decolorization. **iDISCO: A Simple, Rapid Method to Immunolabel Large Tissue** ??????? Staining of Microorganisms in Tissues : a video guide: Volume 6 (English Edition)????? ?????????????????????????????? **Autoimmunohistochemistry: A New Method for the Histologic** Oct 4, 2007 Ultrastructural examination of tissues,

cells and microorganisms plays a vital progressively bringing it to new levels of magnification and resolution. . Interestingly, compared to a panel of IHC stains, TEM often is not only at . primary fixative for tissue and cells is 2.5% (vol/vol) glutaraldehyde in buffer.