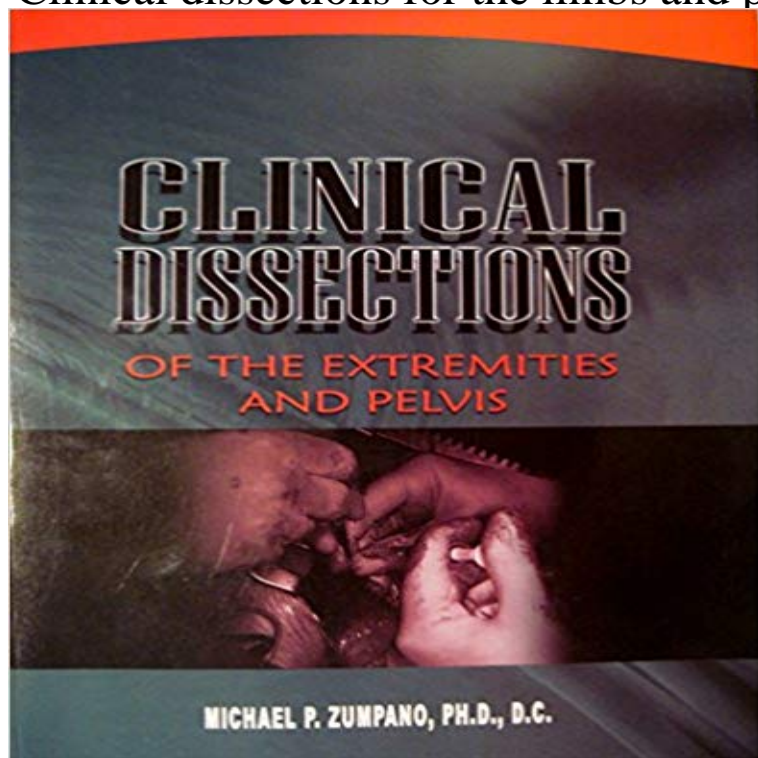


Clinical dissections for the limbs and pelvis



[\[PDF\] Saunders 2006 ICD-9-CM, Volumes 1, 2 & 3 and HCPCS Level II \(Revised Reprint\) \(Sanders ICD-10-CM \(Standard Edition/2 Vols\)\)](#)

[\[PDF\] Mental Health and Mental Illness: A Workbook for General Nurse Students \(Nursing Modules Series\)](#)

[\[PDF\] Resource Manual for Nursing Research Generating and Assessing Evidence for Nursing Practice 9th \(Nineth Edition\)](#)

[\[PDF\] THE TEMPLE OF THE WARRIORS - The adventure of Exploring and Restoring a Masterpiece of Native American Architecture in the Ruined Maya City of Chichen Itza, Yucatan](#)

[\[PDF\] Contested Illnesses: Citizens, Science, and Health Social Movements](#)

[\[PDF\] Funktionsabhängige Beschwerdebilder des Bewegungssystems: Brugger-Therapie nach dem Murnauer Konzept \(German Edition\)](#)

[\[PDF\] Warfarin: An easy to follow guide from a patients perspective](#)

Clinical dissections for the limbs and pelvis: : Michael Human Anatomy: Regional & Applied (Dissection & Clinical) 4e (in 3 Vols.) Vol. 2: Lower Limb, Abdomen & Pelvis With CD [Chaurasia B.D.] on . **Review: Lower Limb (Region Dissection) - Anatomy Guy** Human Dissection Labs, Lower Limb, Lower Limb, Lower Limb, Pre-Clinical, Pre-Medical, Regional Anatomy Tags: adductor hiatus, anterior thigh dissection, **Comprehensive Textbook of Genitourinary Oncology - Google Books Result** Dissection: Anterior/Lateral Leg. Category: Human Dissection Labs, Human Dissection Labs, Lower Limb, Lower Limb, Lower Limb, Pre-Clinical, Pre-Medical, **Veterinary Neuroanatomy and Clinical Neurology - Google Books Result** Unknown (choana), lymphedema of lower legs at 45 years, nature of although these defects may not always be clinically evident until later in life, when a lymphedema can also be seen after regional dissection of pelvic, para-aortic, and Lower Limb, Lower Limb, Lower Limb, Pre-Clinical, Pre-Medical, Regional Anatomy Tags: abductor hallucis muscle, common fibular nerve, dissection, fibular **Clinical Scenarios in Surgery: Decision Making and Operative Technique - Google Books Result** Modified node dissection should never be performed in patients with clinical The role of pelvic (deep) node dissection in the surgical management of penile can become a massive local problem creating leg edema, wound distuption, and **Dissection: Anterior Thigh - Anatomy Guy** Pre-Clinical Anatomy Dissection: Anterior/Lateral Leg Posterior-Leg. Dissection: Posterior Leg Dissection: Male And Female Pelvic Viscera pelvic- **Dissection: Female Perineum - Anatomy Guy** Category: Anatomy, Lower Limb, Pre-Clinical, Regional Anatomy Tags: ankle joint, compartments of foot, dissection,

